Imaging strategies prior to Norwood I: what to use when?

Kuberan Pushparajah
King's College London
Guy's and St Thomas' NHS Trust Foundation
kuberan.pushparajah@kcl.ac.uk

Utrecht Sessions

Acknowledgement to Hannah Bellsham-Revell and Evelina London Team

KING'S HEALTH PARTNERS

Guy's and St Thomas' NHS Foundation Trust NHS · Evelina London Children's Hospital · NIHR National Institute for Health Research · King's College London

1

2

What to use

Clinical exam

CXR | ECG

ECHO

CT | CMR | Fluoroscopic angiography

3D print | Computational modelling

3

Prior to initial assessment

- Post-natal or antenatal diagnosis
- Gestation and birth weight
  - sepsis
  - Other congenital anomalies
- Review of antenatal notes
  - RV dysfunction
  - Tricuspid regurgitation
  - Atrial septal restriction: ?lymphangiectasia

4

Useful reference

European Journal of Cardio-Thoracic Surgery 58 (2020) 416–499
doi:10.1093/ejcts/ezaa188

GUIDELINES

Cite this article as: Alphonso N, Angelini A, Barron DJ, Bellsham-Revell H, Blom NA, Brown K et al. Guidelines for the management of neonates and infants with hypoplastic left heart syndrome: The European Association for Cardio-Thoracic Surgery (EACTS) and the Association for European Paediatric and Congenital Cardiology (AEPC) Hypoplastic Left Heart Syndrome Guidelines Task Force. Eur J Cardiothorac Surg 2020;58:416–99.

Guidelines for the management of neonates and infants with hypoplastic left heart syndrome: The European Association for Cardio-Thoracic Surgery (EACTS) and the Association for European Paediatric and Congenital Cardiology (AEPC) Hypoplastic Left Heart Syndrome Guidelines Task Force

Nelson Alphonso[a], Annalisa Angelini[b,*], David J. Barron[c,*], Hannah Bellsham-Revell[d,*], Nico A. Blom[e,*], Katherine Brown[f], Deborah Davis[g,h], Daniel Duncan[h], Mamy Fedrigo[i,*], Lorenzo Gallletti[j], David Hehir[k], Ulrike Herberg[l,*], Jeffrey P. Jacobs[m,*], Katarzyna Januszewska[n,*], Tom R. Karl[o,a] (Chaiman HLHS Guidelines Task Force), Edward Malec[n,*], Bohdan Maruszewski[p,*], James Montgomerie[q], Christian Pizzaro[h,r], Dietmar Schranz[s,*], Amanda J. Shillingford[t] and John M. Simpson[u,*]

5

HLHS subtypes

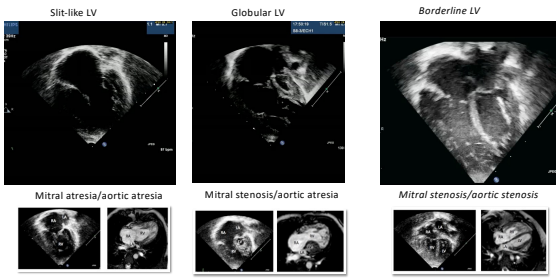

6

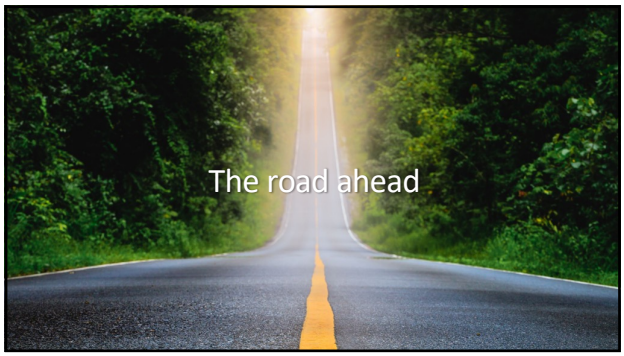

7

What matters?

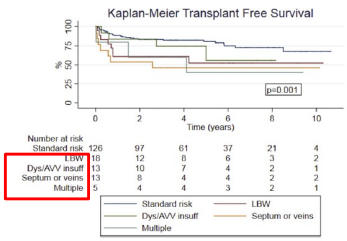

Tanem et al. Ann Thorac Surg 2020; 109:828-34

8

What to look for– Key Points

- Life maintaining structures:
  - Atrial septum
  - Arterial duct
- Tricuspid regurgitation
- Ventricular function
- Pulmonary regurgitation/stenosis
- Pulmonary artery anatomy
- Pulmonary venous abnormalities
- Coronaries
  - Fistulae
- *Potential for use of left heart*
  - *Z-scores*

Alfonso et al: EJCTS 2020:58:416-499

9

Atrial communication

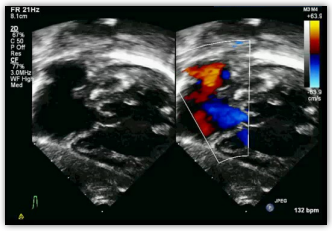

Unrestrictive

10

Atrial communication

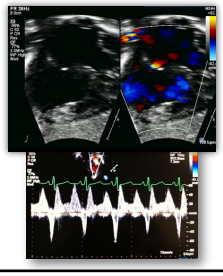

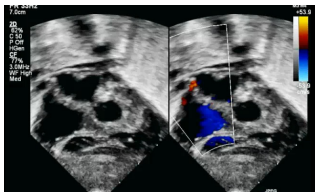

Restrictive

11

Pulmonary lymphangiectasia

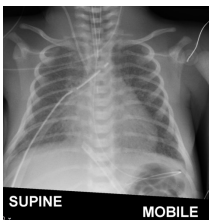

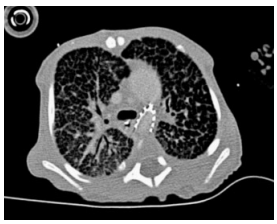

12

Levoatriocardinal vein

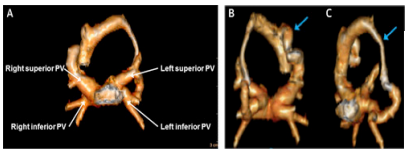

K. Anitha Jayakumar et al. *J Am Coll Cardiol Case Rep* 2019; 1:526-531.

AJR 2015; 205:W162–W171

JACC Case Reports

13

Arterial Duct

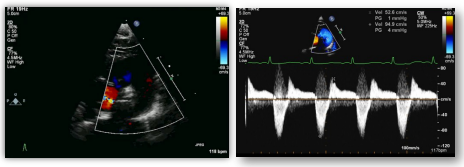

Size/direction of flow/Colour and PW Doppler

14

Arterial duct (*for intervention*)

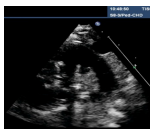

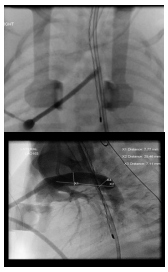

15

Right Ventricular Function

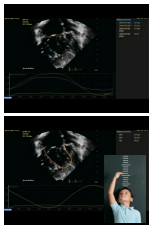

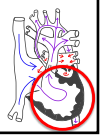

16

Tricuspid Valve

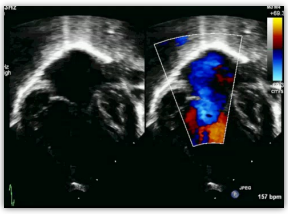

- Often abnormal in HLHS
- Assessment on colour and greyscale, 2D and 3D
- Number and position of jets
- May be exclusion factor for surgery

17

Tricuspid valve

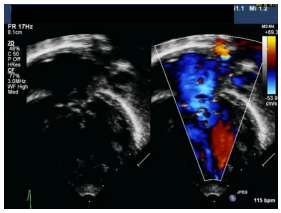

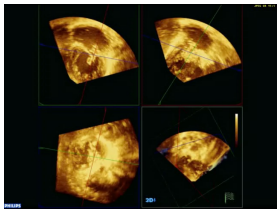

18

Tricuspid valve

Table 3 Primary and secondary mechanisms of regurgitation determined by surgical assessment and echocardiographic review

Variable	Echocardiographic review		Surgical assessment	
	Primary mechanism of regurgitation, *n* (%)	Secondary mechanism of regurgitation, *n* (%)	Primary mechanism of regurgitation, *n* (%)	Secondary mechanism of regurgitation, *n* (%)
Prolapse of leaflet	19 (59)	5 (16)	3 (9)	3 (9)
Restriction of leaflet	2 (6)	12 (38)	0	1 (3)
Annular dilatation	8 (25)	5 (16)	17 (53)	4 (13)
Leaflet dysplasia	3 (9)	5 (16)	14 (44)	12 (38)

Mechanisms of tricuspid valve regurgitation in hypoplastic left heart syndrome: a case-matched echocardiographic–surgical comparison study

Yara Marcelis, Otomi Hoojs, Noti Sebor, Cuci Atila, Andrew Redington, Christopher A. Caldarone, Glen van Arsdell, and Luc Mertens*

19

TV architecture

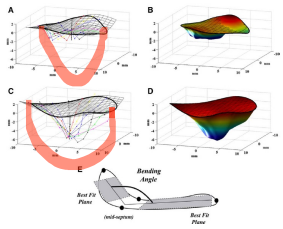

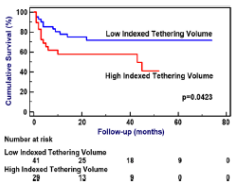

(Circ Cardiovasc Imaging. 2016;7:765-771.)

20

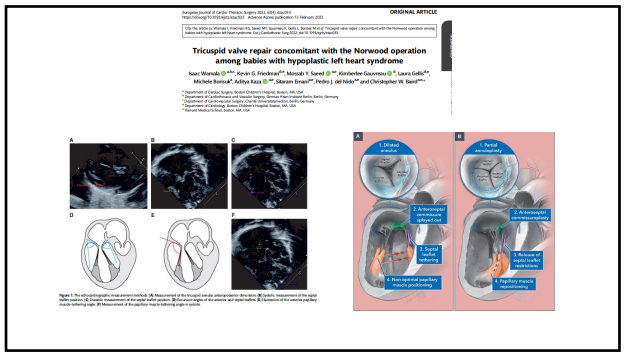

European Journal of Cardio-Thoracic Surgery 2022; 62(4), ezac351
https://doi.org/10.1093/ejcts/ezac351 Advance Access publication 13 February 2022

Cite this article as: Wamala I, Friedman KG, Saeed MY, Guzeloglu A, Gellis L, Borisuk M et al. Tricuspid valve repair concomitant with the Norwood operation among babies with hypoplastic left heart syndrome. Eur J Cardiothorac Surg 2022; doi: 10.1093/ejcts/ezac351

ORIGINAL ARTICLE

Tricuspid valve repair concomitant with the Norwood operation among babies with hypoplastic left heart syndrome

Isaac Wamala [1,2,3], Kevin G. Friedman[4,5], Mossab Y. Saeed [1,6], Kimberlee Gauvreau [1], Laura Gellis[4,5], Michelle Borisuk[4], Aditya Kaza [1,6], Maryam Erman[4,5], Pedro J. del Nido[4,5] and Christopher W. Baird[4,5,*]

[1] Department of Cardiac Surgery, Boston Children's Hospital, Boston, MA, USA
[2] Department of Cardiothoracic and Vascular Surgery, German Heart Institute Berlin, Berlin, Germany
[3] Charité – Universitätsmedizin Berlin, corporate member of Freie Universität Berlin, Berlin, Germany
[4] Department of Cardiology, Boston Children's Hospital, Boston, MA, USA
[5] Harvard Medical School, Boston, MA, USA

Figure 1: The echocardiographic measurement methods. (A) Measurement of the tricuspid annular anteroposterior dimension. (B) Systolic measurement of the septal leaflet position. (C) Diastolic measurement of the septal leaflet position. (D) Excursion angles of the anterior and septal leaflets. (E) Nomenclature of the anterior papillary muscle tethering angle. (F) Measurement of the papillary muscle tethering angle in systole.

21

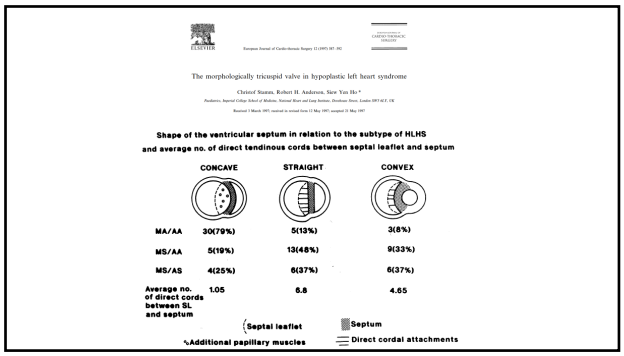

ELSEVIER

European Journal of Cardio-thoracic Surgery 12 (1997) 187–192

EUROPEAN JOURNAL OF CARDIO-THORACIC SURGERY

The morphologically tricuspid valve in hypoplastic left heart syndrome

Christof Stamm, Robert H. Anderson, Siew Yen Ho *

Paediatric, Imperial College School of Medicine, National Heart and Lung Institute, Dovehouse Street, London SW3 6LY, UK

Received 3 March 1997; received in revised form 12 May 1997; accepted 21 May 1997

Shape of the ventricular septum in relation to the subtype of HLHS and average no. of direct tendinous cords between septal leaflet and septum

	CONCAVE	STRAIGHT	CONVEX
MA/AA	30(79%)	5(13%)	3(8%)
MS/AA	5(19%)	13(48%)	9(33%)
MS/AS	4(25%)	6(37%)	6(37%)
Average no. of direct cords between SL and septum	1.05	6.8	4.65

22

Pulmonary Artery/valve

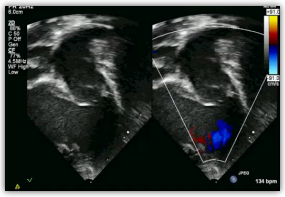

- The "new" systemic valve
- Degree of regurgitation
- Degree of stenosis, dysplasia
- Doppler, greyscale and colour assessment

23

Branch Pulmonary Arteries

- Good size essential for a good surgical result at all stages
- Greyscale and colour assessment, plus Doppler

24

Branch pulmonary arteries

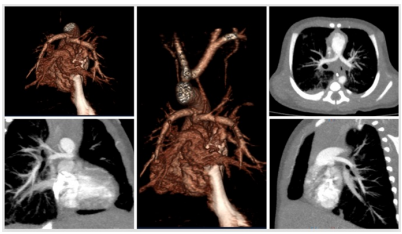

Additional information from CT

25

Pulmonary Venous Drainage

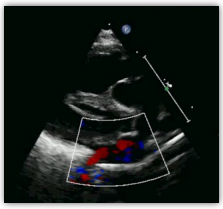

- Anatomy
- Obstruction
- Dopplers

- Association with abnormal pulmonary venous drainage

26

Abnormal pulmonary venous drainage

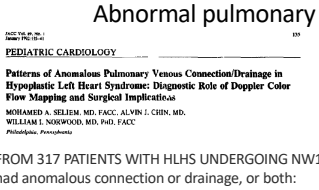

PEDIATRIC CARDIOLOGY

Patterns of Anomalous Pulmonary Venous Connection/Drainage in Hypoplastic Left Heart Syndrome: Diagnostic Role of Doppler Color Flow Mapping and Surgical Implications

MOHAMED A. SELJEM, MD, FACC, ALVIN J. CHIN, MD, WILLIAM I. NORWOOD, MD, PhD, FACC

Philadelphia, Pennsylvania

FROM 317 PATIENTS WITH HLHS UNDERGOING NW1 20(6.3%) had anomalous connection or drainage, or both:

1) Partial anomalous connection and drainage (N=2):
   RPV TO RSVC , RPV TO LSVC
1) Total anomalous connection and drainage (N=8)
2) Normal connection with total anomalous drainage (N=8)
   LEVOATRIOCARDINAL VEIN
3) Normal connection with partial anomalous drainage (N=2)
   – RIGHT PV TO RIGHT OF DEVIATED SEPTUM

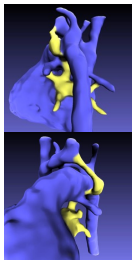

TAPVD ON FETAL CMR AT 32 WEEKS

27

Abnormal pulmonary venous drainage

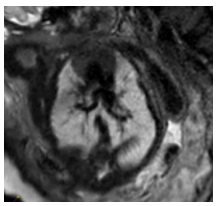

Fetal CMR

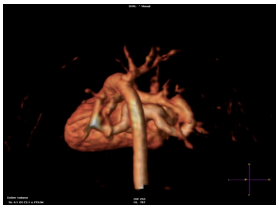

Postnatal CMR

28

Coronary Arteries

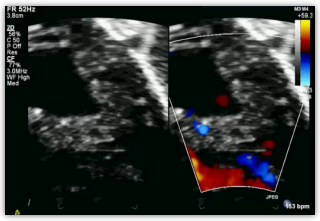

- Usually normal arrangement [1]
- Association with fistulae to LV: MS/AA
- Seem to be of less consequence than in PA/IVS [1,2]

1. Vida VL. J Thorac Cardiovasc Surg 2008;135:339–46.
2. Lloyd TR et al. Am Heart J 1986;112:666–71.

29

Ascending Aorta and Arch

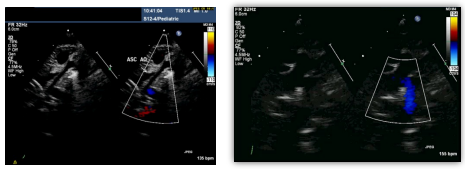

- Size of ascending aorta and arch
- Degree of hypoplasia/focal CoA
- Direction of flow in Ao arch

30

Echocardiography for complex arch anatomy

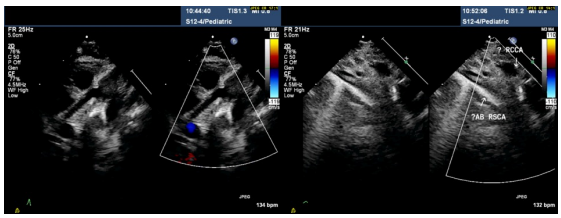

31

MRI of aortic arch

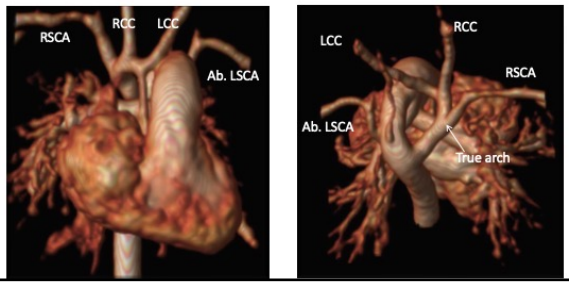

32

MRI: Adequacy of LV

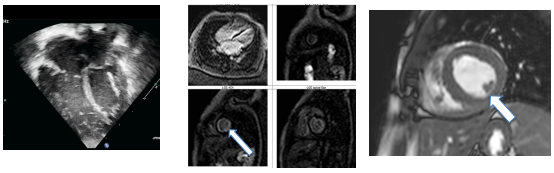

- Neonate – LV volumes
- Presence and extent of EFE [2]
- Mitral Valve size and Papillary Muscle Morphology.[3]

1.Minich LL, et al. Am Heart J 1997;133:570–4
2.Tun G et al. Pediatr Cardiol. 2013 Oct;34(7):1567-76
3.Velasco Forte et al, Abstract SCMR Scientific Session 2015

33

3D Printing: only for complex (non NW1)

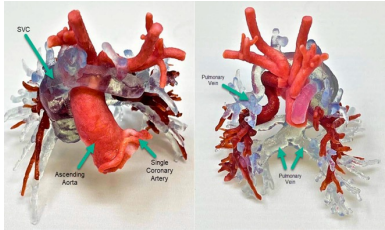

RAI, unbalanced AVSD (hypoplastic LV), TAPVD, pulmonary atresia disconnected PAs

Circ Cardiovasc Imaging. 2022;15:e014260

34

Statistical shape analysis

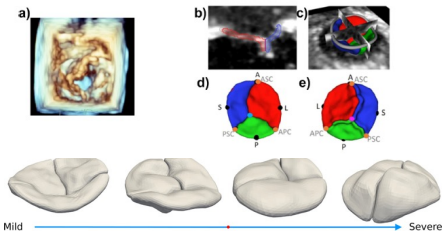

Stat Atlases Comput Models Heart 2022 September ; 13131: 132–140.

35

CASE SELECTION/ STRATIFICATION

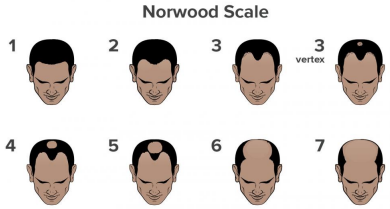

Norwood OT. Male pattern baldness: Classification and incidence. South Med J. 1975;68:1359–65

36

What to use/when

Preoperative assessment of classical hypoplastic left heart syndrome		
Recommendations	Class[a]	Level[b]
Transthoracic echocardiography is sufficient to plan initial surgery in most cases	I	C
CT or MRI should be performed because of anatomical concerns (e.g. pulmonary venous drainage path)	I	C
Chest CT for clinical suspicion of lung disease such as pulmonary lymphangiectasia	I	C
Angiography should principally be used when catheter intervention is being considered	I	C
3D echocardiography may assist in imaging the tricuspid valve to assess morphology and regurgitation	I	C
Additional features in the preoperative assessment of hypoplastic left heart complex		
The size of the left heart structures should be measured and the z-scores, calculated	I	C
Cardiac MRI may be used to define the extent of EFE	IIb	C
Predictive scores can be used to aid decision-making for SV versus bi-V circulation in critical AS	IIa	C
Predictive scores can be used to aid decision-making for SV versus bi-V circulation in unbalanced AVSD	IIa	C

Alfonso et al: EJCTS 2020:58:416-499

37

38